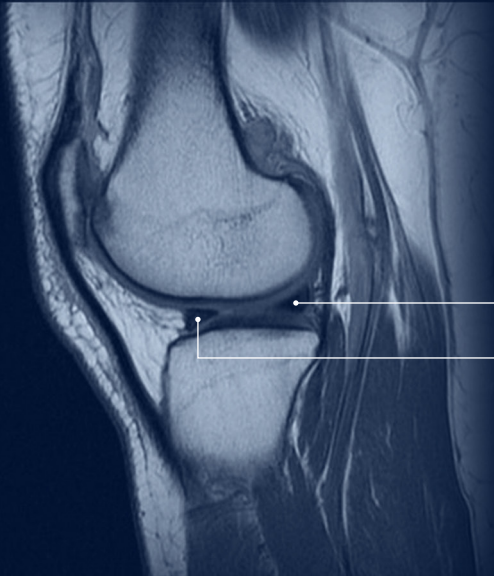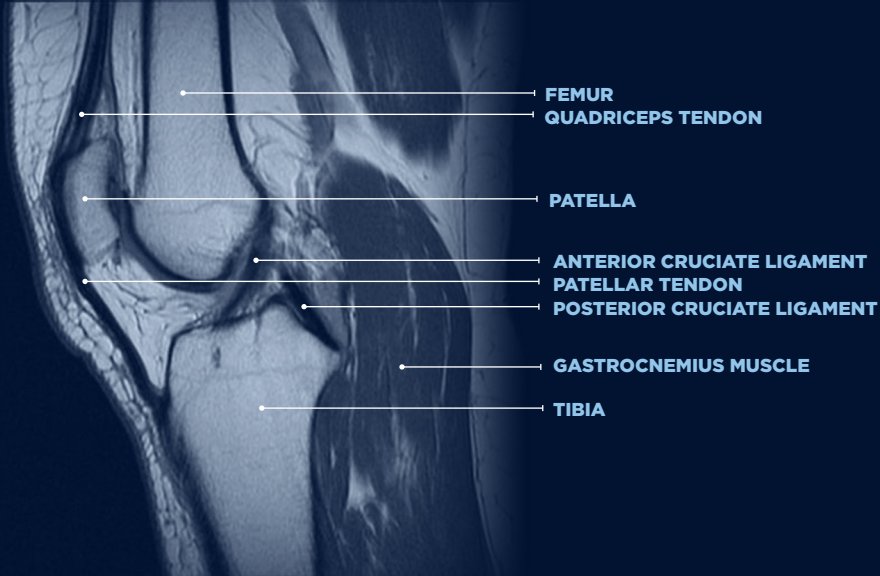


LATERAL MENISCUS, POSTERIOR HORN

LATERAL MENISCUS, ANTERIOR HORN



FEMUR

QUADRICEPS TENDON

PATELLA

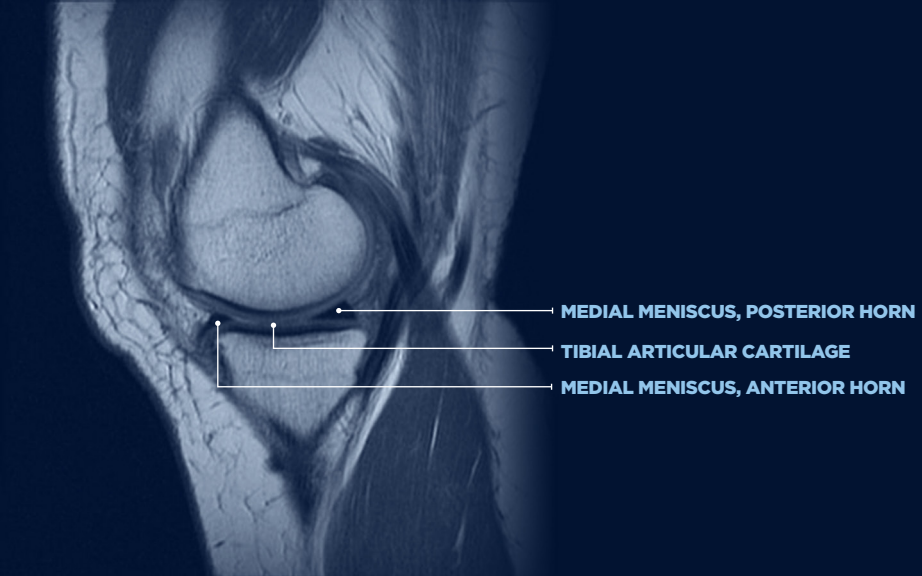
ANTERIOR CRUCIATE LIGAMENT

PATELLAR TENDON

POSTERIOR CRUCIATE LIGAMENT

GASTROCNEMIUS MUSCLE

TIBIA

An MRI scan of a knee joint in a sagittal view. The femur is at the top, and the tibia is at the bottom. The meniscus is visible between the two bones. Three white lines with dots at the end point to specific parts of the meniscus and the articular surface. The labels are in white text on the right side of the image.

MEDIAL MENISCUS, POSTERIOR HORN

TIBIAL ARTICULAR CARTILAGE

MEDIAL MENISCUS, ANTERIOR HORN